


AFRICAN START-UP PITCHES



Conrad Tankou

CEO

GIC Space

Providing Universal Access to Breast and Cervical Cancer Screening in SSA

Conrad Tankou MD
CEO



09/03/2023

le 09/03/2023

29 yrs


Breast lump + pain
for 3 months

Suspected Cancer

3 months to seek care

3 months to get a diagnosis

Laboratoire National de Santé Publique et de Référence
Boite Postale [redacted] YAOUNDE
web : <http://www.pasteur-yaounde.org>
ANALYSES MEDICALES


CENTRE PASTEUR
DU CAMEROUN

Date de Naissance : 29/01/1994
Prelevé le 13/05/2023 à 20:16
Enregistré le 13/05/2023 à 20:16
Edité le 06/06/2023 à 10:29

Sample collected: 13/5/23

Results available: 06/06/23

HISTOPATHOLOGIE

CENTRE PASTEUR
DU CAMEROUN

EXAMEN MICROSCOPIQUE

Les deux nodules montrent des lésions identiques. Le matériel examiné montre au sein d'un tissu mammaire une prolifération tumorale maligne faite de cellules glandulaires atypiques. Ces cellules sont disposées en massifs cellulaires. On note un pléomorphisme cellulaire marqué. Les noyaux sont arrondis ou ovales, hyperchromatiques d'aspect granulé avec 1 à 2 nucléoles visibles. On dénombre 7 figures de mitoses sur 10 champs au fort grossissement. Il s'y associe de nombreux foyers de carcinome in situ de haut grade avec comédonécrose. On ne note pas d'embolus vasculaires péritumoraux. Les remaniements fibreux contiennent de nombreux foyers de carcinome in situ de haut grade. La limite supérieure est infiltrée. Les 2 nodules parvenus dans le deuxième contenant correspondent à des ganglions infiltrés.

CONCLUSION

Pièce de nodulectomie avec curage axillaire montrant des aspects histopathologiques de carcinome canalaire de grade III de Nottingham avec un score de Scarff-Bloom et Richardson modifié par Elston et Ellis 8 (3+3+2) ;

- Absence d'embolus péritumoraux ;
- Présence de carcinome in situ avec comédonécrose ;
- Limite supérieure infiltrée ;
- absence de maladie de Paget et d'extension rétro-mammaire ;
- Deux ganglions infiltrés

- Classification pTNM (AJCC, 8ème édition 2017) = pT2 pN1a M0

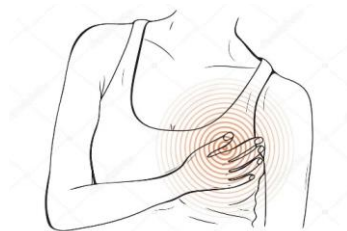dans notre laboratoire est souhaitable à la recherche de la surexpression du Her2 et des récepteurs hormonaux.

Confirmed breast cancer

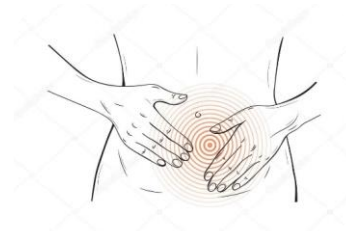THE PROBLEM

In SSA overall prevalence of breast cancer screening = **12.9%** only

9 in 10 women who die from cervical cancer are in **developing countries**



31% Breast Cancer



23% Cervical Cancer




Scarcity of medical
specialists



Lack of access
(currently 5%)

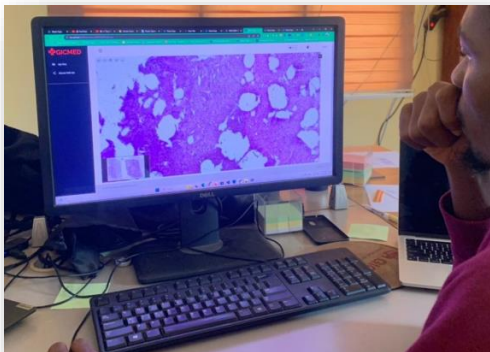


90% discovered at
late or end stage

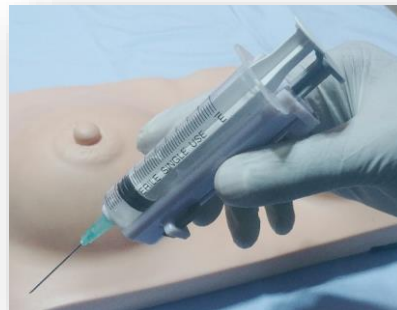


Rising incidence

...remote screening at the point of care!



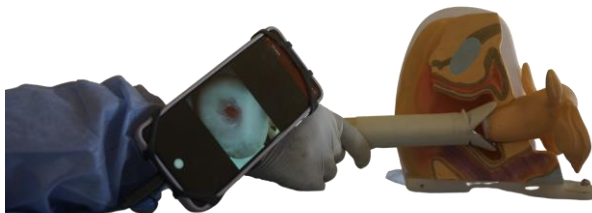**Digital microscopy
system/Telepathology**




**Fine needle
biopsy device**



Telemedicine platform



Smart speculum (C-Spec)



Gamified 3D platform

#Adaptable

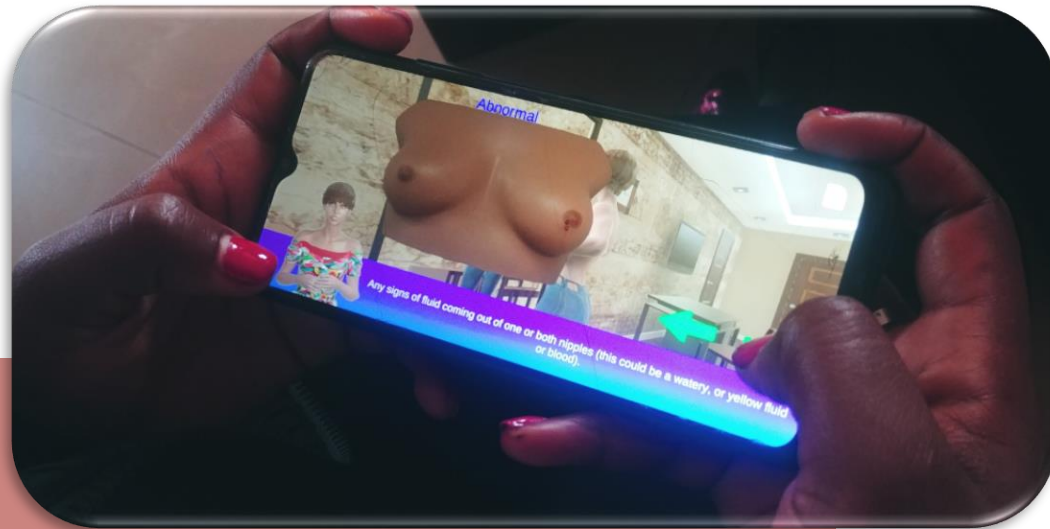

#Reliable

#Faster

#PointOfCare

#Affordable

3D Gamified learning/training For health providers + general population



#Intuitive

#Captivating

#Engaging

#Offline

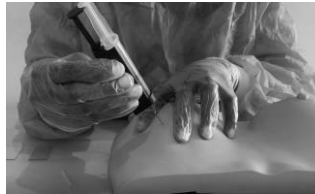
#Easy

#Linkage to care

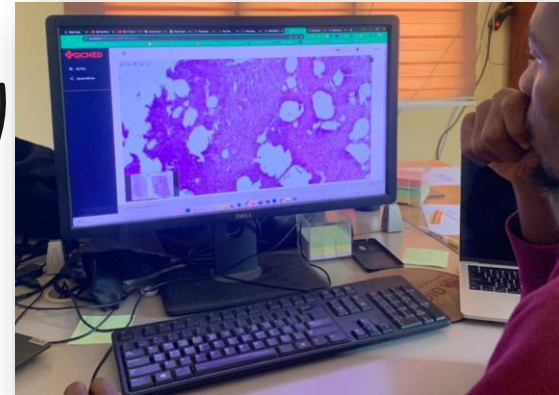
#Self pace

Screening process...

**1. Required data
captured at the point of
care with GICMED Tech**



**2. Instant
review and
diagnosis by
a Specialist**



**3. Results Received
at the point of care**




**24-72 hrs
vs
1- 4 Months**

#PointOfCare #Faster #Cheaper

Treatment options

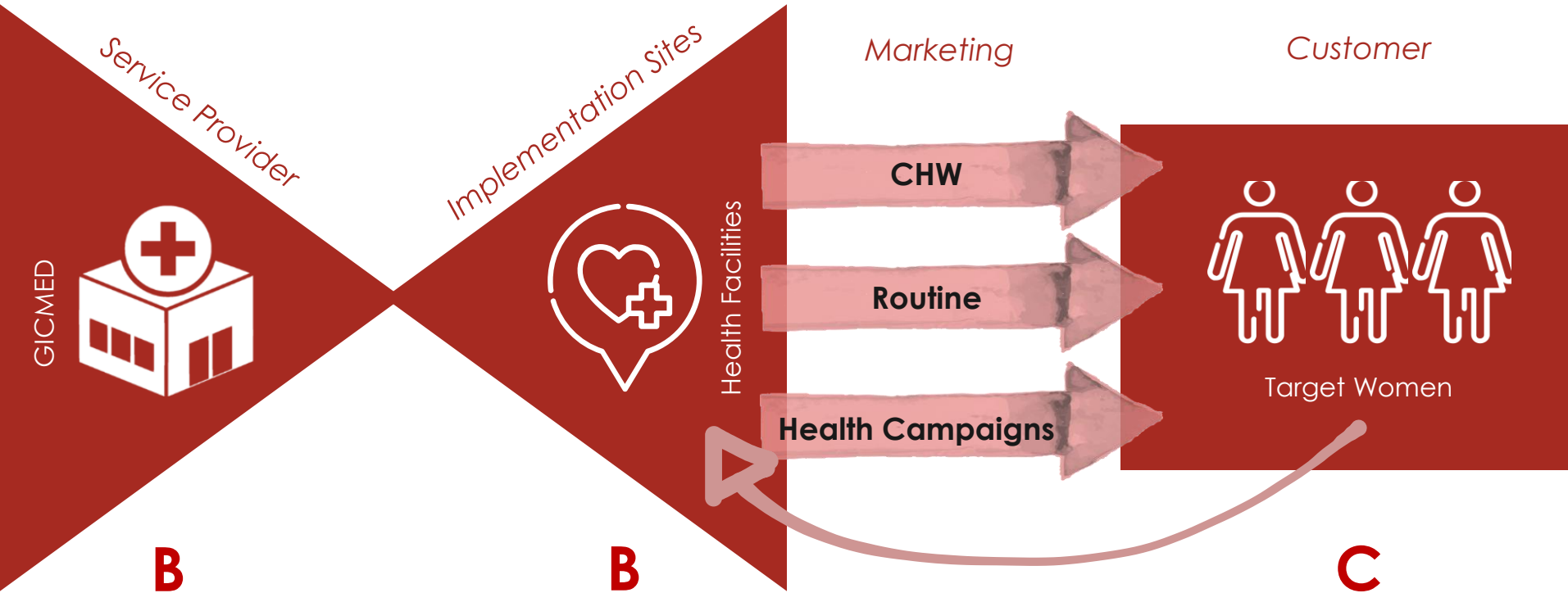


**Tracking patients to the nearest
treatment facility**
(advanced cervical lesions +
breast lesions)



**Mobile treatment unit system with
thermocoagulation**
(early-stage cervical lesions)

Our implementation model



Providing/Leasing Technologies to Hospitals

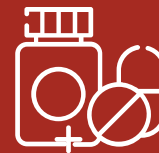Other revenue Sources



*3D platform
Freemium*



Pathology analysis



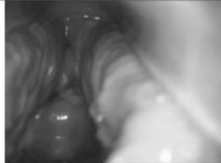

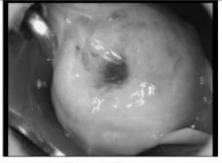

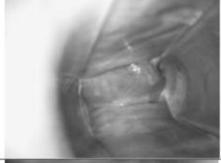

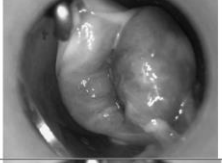



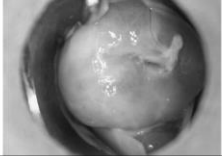

*POC
Treatment*

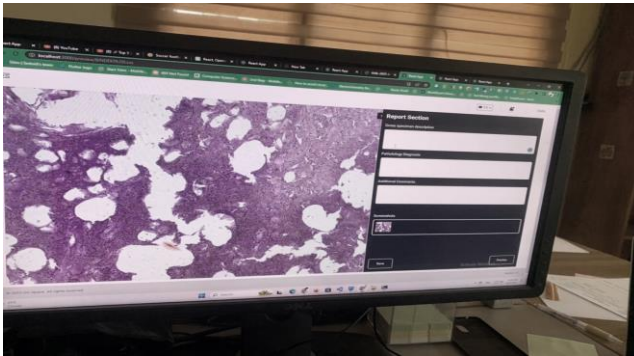
COMPETITION

	GICMED	Specialized Hospitals	Mobile OTD (East Africa)
Cost	✓	✗	✗
Both Breast and Cervical Cancers	✓	✓	✗
Speculum + colposcope in 1 device	✓	✗	✗
E-Records	✓	✗	✓
Patient tracking	✓	✗	✓
Access to treatment	✓	✓	✗
Enables remote examination in real time	✓	✗	✓
Faster examination time	✓	✗	✗
Enables 2nd and 3rd opinions	✓	✗	✓

Particularly adapted to the African context!

SOLUTION

Traditional Speculum		Our Smart Speculum	
Poor visibility, patient discomfort		Significant increase visibility, NO patient discomfort	
Image of cervix	Pain level	Image of Cervix	Pain level
	4  Moderate Pain		0  No Pain
	6  Severe Pain		0  No Pain
	4  Moderate Pain		0  No Pain



I honestly think every hospital should adopt C-Spec by GICMED. The level of comfort for women is highly remarkable. And I got to see my cervix in real time.

Geraldine.

Client

I have never seen my patients as comfortable as they are now during speculum examination. This is really a revolution in FemTech.

Dr Tahtah Fritz

Doctor

Having a Colposcope and a speculum in one portable and easy to use device, what more to say about such an ingenious product.

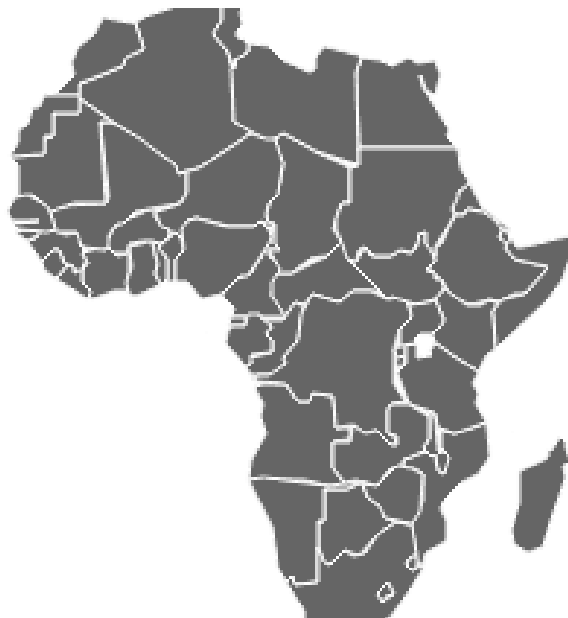Dr Solomon A.

Doctor

Market Size

**Target Women aged between 21 years +
= 400M+**

**Target health facilities =
500k+**






MISANTE

Ministère de la Santé Publique

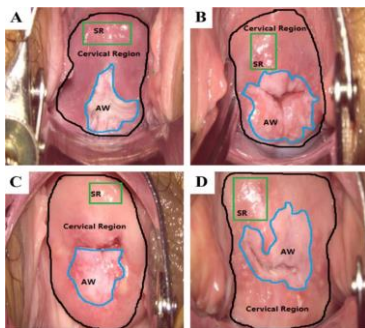


Institut Pasteur

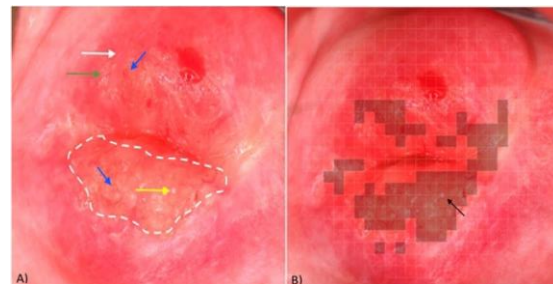
Central Africa Republic



Cervical Cancer



Female Genital Schistosomiasis





THANKS!

E-mail: info@gictelemed.org

Phone: +237 691 89 61 65

Web: www.gictelemed.org

